

available at www.sciencedirect.comjournal homepage: www.ejconline.com

Role of contrast-enhanced ultrasound in the blinded assessment of focal liver lesions in comparison with MDCT and CEMRI: Results from a multicentre clinical trial ☆

F. Tranquart^{a,*}, A. Le Gouge^b, J.M. Correas^c, V. Ladam Marcus^d, P. Manzoni^e, V. Vilgrain^f, C. Aube^g, M.F. Bellin^h, L. Chamiⁱ, M. Claudon^j, M. Cuilleron^k, J. Drouillard^l, B. Gallix^m, O. Lucidarmeⁿ, D. Marion^o, A. Rode^p, J.P. Tassu^q, H. Trillaud^r, A. Fayault^a, E. Rusch^s, B. Giraudeau^b

^aCIC-IT Ultrasons-Radio Pharmaceutiques, INSERM U930-CNRS 2448, Université François Rabelais, Hôpital Bretonneau, CHRU Tours, 37044 Tours Cedex 9, France

^bCIC INSERM 202, Hôpital Bretonneau, CHRU Tours, 37044 Tours Cedex 9, France

^cService de Radiologie Adultes, Hôpital Necker, AP-HP, 75743 Paris Cedex 15, France

^dService de Radiologie et Imagerie Médicale, Hôpital Robert Debré, CHU Reims, 51092 Reims Cedex, France

^eService de Radiologie C, Hôpital St Jacques, CHU Besançon, 25000 Besançon, France

^fService de Radiologie et d'Échographie, Hôpital Beaujon, AP-HP, 92118 Clichy Cedex, France

^gService de Radiologie A, CHU Angers, 49033 Angers Cedex 01, France

^hService de Radiologie, Hôpital Paul Brousse, AP-HP, 94804 Villejuif, France

ⁱService d'Échographie, Institut Gustave Roussy, 94805 Villejuif, France

^jService de Radiologie, Hôpital d'Enfants, CHU Nancy, 54511 Vandœuvre Les Nancy, France

^kService de Radiologie, Hôpital Nord, CHU Saint Etienne, 42055 St Etienne Cedex, France

^lService d'Imagerie Médicale, Hôpital Haut-Lévêque, USN, CHU Bordeaux, 33604 Pessac cedex, France

^mService d'Imagerie Médicale, Hôpital St Eloi, CHRU Montpellier, 34295 Montpellier Cedex 5, France

ⁿService de Radiologie, Hôpital La Pitié Salpêtrière, AP-HP, 75651 Paris Cedex 13, France

^oService de Radiologie, Hôpital Hôtel Dieu, HCL, 69002 Lyon, France

^pService de Radiologie, Hôpital de La Croix Rousse, HCL, 69317 Lyon Cedex 04, France

^qService d'Imagerie Médicale, Hôpital de la Milétrie, CHU Poitiers, 86000 Poitiers, France

^rService de Radiologie, Hôpital St André, CHU Bordeaux, 33075 Bordeaux, France

^sService Information Médicale, Epidémiologie et Economie de la Santé, CHRU Tours, 37044 Tours Cedex 9, France

☆ Sponsored by unrestricted educational grant from Bracco International BV.

* Corresponding author: Tel.: +33 2 47 47 38 48; fax: +33 2 47 47 38 76.

E-mail address: tranquart@med.univ-tours.fr (F. Tranquart).

1359-6349/\$ - see front matter © 2008 Elsevier Ltd. All rights reserved.

doi:10.1016/j.ejcsup.2008.06.003

ARTICLE INFO

Article history:

Received 9 May 2008

Received in revised form 20 June 2008

Accepted 20 June 2008

Keywords:

Liver

Contrast-enhanced sonography

CT-scan

Contrast-enhanced-MRI

ABSTRACT

The main aim of this multicentre prospective study was to determine the clinical value of SonoVue® administration for the characterisation of focal liver lesions incidentally detected in oncological or cirrhotic patients.

Eight hundred and seventy four consecutive patients with 1034 nodules (diameter between 5 and 100 mm) not fully characterised by conventional US or previous single-phase CT-scan were imaged using real-time contrast-enhanced scanning after intravenous injection of 2.4 ml of SonoVue®. Blinded off-site assessment was conducted to evaluate the diagnostic performance of contrast-enhanced ultrasound (CEUS) in comparison with gold standard, i.e. triphasic CT-scan or contrast-enhanced MRI or histology.

In the differentiation between benign and malignant lesions, CEUS yielded a sensitivity of 79.4% and a specificity of 88.1%. In the subgroup of patients with cirrhosis, the kappa value for off-site diagnosis between CEUS and reference modality was slightly lower compared to the non-cirrhotic group: 0.42 and 0.66 ($p = 0.0002$), respectively. The concordance rate and kappa value of CEUS for benign to malignant differentiation between on-site and blinded review were 90.2% and 0.80%, respectively, compared to 83.4% and 0.66%, respectively, for the reference imaging technique.

These results indicate that CEUS using SonoVue® is a competitive and effective diagnostic tool for the characterisation of focal liver lesions compared to other modalities such as CT and MR imaging.

© 2008 Elsevier Ltd. All rights reserved.

1. Introduction

Worldwide, ultrasound is the first imaging modality for screening focal liver lesions in various situations such as abdominal pain, dyspeptic syndrome or cancer staging. Because of either patient or technical limitations, the sensitivity of conventional sonography remains poor (between 55% and 70%)^{1,2} and generally lower than with other modalities such as Computed Tomography (CT) or Magnetic Resonance Imaging (MRI).³ Moreover, once a lesion has been detected, the foremost question is always the differentiation of benign or malignant lesions. These limitations are reinforced by the non-specific ultrasound pattern of focal liver lesions even when using modern methods including harmonic, compounding or Doppler imaging. The higher accuracy reported with CT and MRI is partly related to the use of contrast agents which allows the description of specific vascular patterns whatever the tissue specificity is. The use of contrast agents is therefore pivotal in the detection and the characterisation processes, whatever the imaging modality is.

The characterisation of focal liver lesions using the imaging faces many challenges due to the high incidence of lesions incidentally discovered during abdominal examinations, limited access to some imaging techniques, cost, patient compliance and its efficiency.

Another frequent limitation reported for conventional sonography is reliability and reproducibility described as operator-dependant. On the contrary, CT and MR techniques are known for their high reliability and their easy review for further comparison. The US limitation is related to many factors, including inappropriate delineation in terms of limits or contrast, poor lesion identification on still images, absence of standard cine-loops for review of complete examination, differences between machine performances


and display as well as its dependence on operator experience. Sonography is often limited to the detection of abnormalities in the general population whilst CT or MRI is used at a second stage to confirm the diagnosis and thus guides the treatment.⁴

The combined development of ultrasound contrast agents and non-linear imaging at low acoustic power has improved diagnostic imaging accuracy.⁵ Real-time imaging has greatly simplified the scanning technique making it comparable to conventional US. Moreover, the improved contrast to tissue ratio between the lesion itself and the surrounding tissue, and the possibility of studying the contrast kinetics have allowed the detection and characterisation of lesions not visible or poorly visible on either conventional sonography or other modalities. In the recent years, an increasing interest^{6–15} on the use of CEUS has been reinforced by the publication of the European EFSUMB guidelines for contrast agents in ultrasound.¹⁶ However, the number of multicentre studies is limited, and the lack of pharmaco-economical studies remains a problem.

The main aim of this multicentre prospective study was to determine the clinical value of SonoVue® injection for the characterisation of liver nodules detected incidentally but not fully characterised by conventional US or CT-scan.

2. Subjects and methods

A total of 874 consecutive patients, involving 1034 nodules with adequate imaging, were included in this multicentre prospective study between May 2005 and December 2007. Fifteen radiology centres with expertise in liver imaging participated in the trial (Table 1). The patient population characteristics were as follows: 438 females and 436 males mean age 55.7 +/- 17.9 years and mean body weight 71.2 +/-

Table 1 – Total number of patients and nodules per centre involved in this study

15.1 kg. Informed consent was obtained before enrolment according to Ethical Committee approval. The study was sponsored by a national grant from French Health Ministry.

The inclusion criteria were the presence of one to three liver lesions with a diameter between 5 and 100 mm not fully characterised by conventional US or previous single-phasic CT-scan and the availability of a gold standard, i.e. an imaging examination (three or four phase contrast-enhanced CT or contrast-enhanced MR imaging within 30 d) or pathology (biopsy or surgical specimen within 6 months).

The diagnostic judgements were obtained by off-site diagnosis, performed by two independent senior radiologists for CEUS and one independent senior radiologist for the reference modality, blinded to the final on-site diagnosis.

A gold standard diagnosis was obtained for 862 nodules: in 184 nodules (21.3%), the diagnosis was based on histology. For the remaining 172 nodules, no data were available due to missing examinations ($n = 54$) or non-readable examinations ($n = 65$).

Amongst the 862 nodules with a gold standard, 129 examined with CEUS were excluded (CEUS not performed or of poor quality or no visible lesions) thus leading to a cohort of 733 nodules with both examinations (Table 2).

3. US imaging technique

US scanning was performed by physicians with more than ten years experience of liver imaging using the Sequoia 512 scanner (Siemens-Acuson, CA, USA) with a curved 4C1 transducer and CPS mode (487 examinations) or Aplio scanner (Toshiba, Japan) with 6C1 transducer and pulse subtraction imaging or VRI modes (348 examinations). The remaining 39 examinations were performed on various scanners (Logiq9, GE, USA; Elegra and Antares, Siemens, USA; IU22, Philips, USA). Prior to contrast-enhanced imaging, all patients underwent conventional sonography with fundamental or tissue-harmonic

modes using optimised settings for B-mode and Doppler imaging. One or two cine-loops were stored.

After completion of the baseline scanning, one or two boluses of SonoVue® Bracco, Italy (2.4 ml each) per nodule were injected intravenously each followed by a 5 ml normal saline flush. A time-delay of 10 min was observed when two injections were required for the same nodule to allow microbubbles to wash out.

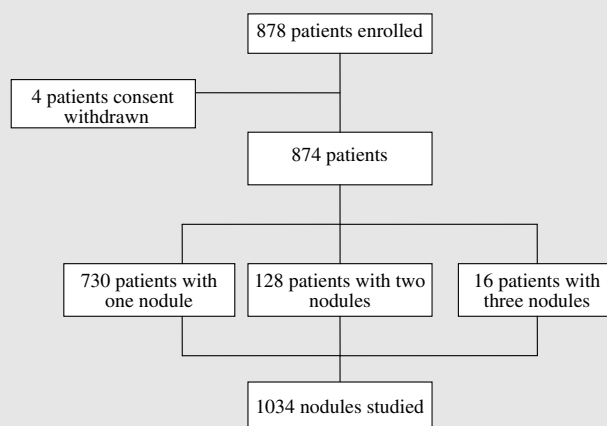
Real-time contrast-enhanced scanning using low MI techniques was started as soon as the contrast agent was injected and was terminated when the contrast had disappeared, i.e. from 4.5 to 7 min. Three cine-loop recordings were obtained during enhancement and stored for blinded review: the first one between 5 and 35 s, the second one between 60 and 90 s and the last one between 150 and 180 s after injection. Single frames and cine-loops were stored on hard disk in DICOM format, and compressed to MPEG4 for further review.

4. Image interpretation

The number, size and location of liver lesions were documented on schematic liver charts using the Couinaud classification in order to match with the lesion identified by the reference modality.

The characterisation of focal liver lesions (FLL's) was performed according to the criteria defined by the Consensus Conference in Rotterdam.¹⁶

On-site diagnosis was performed by a senior radiologist at the time of the examination, and was based on the review of both baseline and CEUS examination. Off-site diagnosis was performed by two independent senior radiologists blinded to the final on-site diagnosis and the reference modality. The only data available for blinded reviewers were the indication for the examination and the location of the FLL, as drawn by the on-site investigator on the liver chart. The blinded reviewers were chosen amongst the principal investigators

Table 2 – Number of patients and number of nodules studied**Table 3 – Main Lesions Characteristics: largest diameter, depth relative to the skin and volume of SonVue® injected by lesion.**

	Available data	Mean	SD
Diameter (mm)	1031	29.67	20.68
Skin-lesion distance (cm)	1005	5.93	2.65
Injected volume (ml)	1034	3.10	1.20

selected randomly from study centres located in different towns. In the case of discrepancy between the two blinded reviewers, a final consensus diagnosis was obtained by an expert committee including 5 senior radiologists.

5. Reference imaging

CT-scan and MRI were performed according to up-to-date optimised protocols. The multidetector CT examination included at least three phases, one acquired before contrast administration and two acquired after injection of an iodinated contrast agent with low osmolality (2 ml/kg bw, 350 mg/ml) administered at a rate of 3 ml/s. The acquisition during the arterial phase started 20–30 s after injection, or was synchronised with a bolus tracking technique. It was followed by a portal-venous phase acquisition starting 60–70 s after the start of the injection. The collimation did not exceed 5 mm, and the pitch was adapted to cover the entire abdomen within a single breath-hold.

The MR imaging protocol included at least a T2-weighted spin-echo sequence, a T1-weighted spin-echo or gradient-echo sequence and a dynamic T1-weighted gadolinium-enhanced study during a breath-hold. Post-contrast arterial, portal and delayed scans were acquired. The slice thickness was below 8 mm, and the inter-slice gap was limited to below 20% of the slice thickness.

Both examinations were interpreted on-site by an experienced radiologist blinded to sonographic findings. The size, location and type of each lesion was documented on the anatomical map. Each reference examination was reviewed blind off-site by a senior radiologist with information limited to examination indications and subject description.

The indication for pathology (by either US or CT guided biopsy or surgery) was based on the medical history and the on-site image findings, and was not influenced by the contrast-enhanced US study.

Off-site reference imaging diagnosis, CEUS diagnosis and pathology were obtained for 121 focal lesions.

6. Examination cost

We compared the examination costs of the three imaging modalities on the basis of reported costs from French health system. In this perspective, we considered the costs for examination, injection and contrast agent. For CT-scan and MRI, an extra value was considered for technical lump sum.

7. Data analysis and statistical evaluation

The characterisation provided by off-site reviewers of CEUS images was compared to the final diagnosis obtained by reference modality. When pathology was available, this modality was considered as the reference technique irrespective of the results of CT-scan or MRI.

Both on-site CEUS and reference imaging diagnosis were compared to off-site CEUS and reference imaging diagnosis.

Sensitivity and specificity were calculated for each type of lesion with a confidence interval of 95%.

The assessment of inter-reviewer concordance was evaluated using concordance rate and kappa value with a confidence interval of 95%. A statistically significant level was $p < 0.05$.

Table 4 – Concordance of results: contrast-enhanced ultrasound (CEUS) versus Reference modality (CT-scan, MRI, histology) Legend: Hem (Haemangioma), FNH (Focal Nodular Hyperplasia), F Fatty S (Focal Fatty Sparing), F Fatty L (Focal Fatty Liver), Ade (Hepatocellular Adenoma), Reg N (Regenerative Nodule), HCC (HepatoCellular Carcinoma), Met (Metastasis), Chol (Cholangiocarcinoma)

		Biopsy/MRI/CT										
		Cyst	Hem	FNH	F Fatty S	F Fatty L	Ade	Reg N	Abscess	HCC	Met	Chol
CEUS	Cyst	12	0	0	0	0	0	0	0	2	2	0
	Hem	5	123	4	2	6	0	1	0	8	11	0
	FNH	1	4	113	2	3	12	0	0	8	4	0
	F Fatty S	0	2	3	4	0	0	0	0	1	1	0
	F Fatty L	0	3	0	1	11	2	2	0	1	1	0
	Ade	0	1	10	0	0	2	0	0	1	1	0
	RegN	0	0	1	1	2	0	14	1	16	1	1
	Abscess	0	0	0	0	0	0	0	5	0	1	0
	HCC	1	0	4	0	0	3	9	1	120	4	3
	Met	2	10	2	2	3	1	0	1	13	107	1
	Chol	–	–	–	–	–	–	–	–	–	–	–

8. Results

The final diagnosis obtained by the reference modality (off-site review) was hepatocellular carcinoma ($n = 172$), haemangioma ($n = 144$), focal nodular hyperplasia ($n = 137$), metastasis ($n = 135$), fat and focal fatty sparing area ($n = 38$), regenerative nodule ($n = 27$), cysts ($n = 24$), hepatocellular adenoma ($n = 21$), abscess ($n = 8$) and cholangiocarcinoma ($n = 5$).

The mean size of the nodules was 29.67 ± 20.68 mm. The mean depth relative to skin surface was 59.30 ± 26.50 mm. A maximum of 4.8 ml of SonoVue® was injected to characterize a nodule with a mean dose of 3.1 ± 1.2 ml (Table 3).

For the differentiation between benign and malignant lesions, CEUS yielded a sensitivity of 79.4% [min 74.6, max 83.7] and a specificity of 88.1% [min 84.8, max 91]. When the four main liver lesions (haemangioma, focal nodular hyperplasia, metastasis and hepatocellular carcinoma) are considered, the sensitivity was 85.4%, 82.5%, 79.3% and 69.8%, respectively, and the specificity was 93.7%, 94.3%, 92.5% and 94.7%, respectively (Table 4).

The concordance and kappa value of CEUS for benign to malignant differentiation between on-site and blinded review were 90.2% [88.1–92.1] and 0.80 [0.76–0.84], respectively, compared to 83.4% [80.7–85.9] and 0.66 [0.61–0.71], respectively, for the reference imaging technique (Tables 5 and 6). The concordance between reviewers 1 and 2 in the assessment of CEUS diagnosis was 86% [min 83.5, max 88.3], and the kappa value was 0.71 [min 0.7141, max 0.7144].

The concordance and kappa value of CEUS for the characterisation of each liver lesion between on-site and blinded review were 80.7% [min 77.8, max 83.4] and 0.77 [min 0.73, max 0.80], respectively, compared to 72.5% [min 69.3, max 75.6] and 0.67 [min 0.63, max 0.70], respectively, for reference imaging technique. The concordance between reviewers 1 and 2 in the assessment of CEUS diagnosis was 71.4% [min 68.1, max 74.5], and the kappa value was 0.65 [min 0.6530, max 0.6532].

In the subgroup of patients with available pathology, the concordance rate and kappa value were not different for CEUS [64.5% (min 55.2, max 73.0) and 0.53; (min 0.42, max 0.63), respectively] and the reference imaging technique [67.8% (min 58.7, max 76.0) and 0.58; (min 0.47, max 0.68), respectively].

In the subgroup of patients with cirrhosis, the kappa value for off-site diagnosis between CEUS and reference modality was slightly decreased compared to the non-cirrhotic group: 0.42 and 0.66 ($p = 0.0002$), respectively, whilst concordance rates remained similar, 71.8% [64.9–78.0] versus 73.5% [69.4–77.3] ($p = 0.65$), respectively.

The reported costs are slightly lower for CEUS than for CT-scan, and are largely lower for MR in relation to a marked difference in the technical lump sum between CT-scan and MRI (Table 7).

9. Discussion

The introduction of US contrast agents has changed the impact of liver ultrasonography by increasing the number of lesions correctly detected and characterised thus reaching the level of other imaging modalities.^{6–15} These observations make the US a valuable initial imaging modality, as currently used, as well as a cheap technique able to provide a complete

Table 5 – Comparison between on-site and blinded off-site MRI/CT imaging assessments

		MRI/CT on-site		
		Malignant	Benign	Total
Blinded review MRI/CT	Malignant	286	74	360
	Benign	64	408	472
Total		350	482	832

Table 6 – Comparison between on-site and blinded off-site CEUS imaging assessments.

		CEUS on-site		
		Malignant	Benign	Total
Blinded review CEUS	Malignant	316	37	353
	Benign	50	488	538
Total		366	525	891

Table 7 – Comparison of the total costs for the three imaging modalities, CEUS, CT-scan and MRI

Costs (in €)	CEUS	CT-scan	MRI
Exam	75.60	61.55	69
Injection	9.60	9.60	9.60
Contrast agent	70	20	30
Technical lump sum		100.50	213.70
Total cost	155.20	191.65	322.30

Total costs are determined on the basis of reported costs from French health system considering the costs for examination, injection and contrast agent A specific additional technical lump sum was added for CT-scan and MRI.

diagnosis in one session without irradiation in anxious patients after the discovery of a liver lesion.

The results obtained in this study are similar to the previously reported single center series¹⁷⁻²³ with a tendency to lower sensitivity and specificity. The first explanation would be that this is a multicentre study in which all physicians do not have the same experience in performing ultrasound examinations with contrast agents. Some have an extensive experience with more than 1000 examinations performed, whilst others have recently acquired an experience based on fewer than 300 exams. This might explain the discrepancy of acquisitions. Secondly, there were some differences in the settings or performance of various machines used in this study related to body habitus or lesion types, which could explain some differences in the review process. A final explanation would be that the results are based on a strict off-site review process which reduces the final performances of the method under evaluation. Despite a strict acquisition protocol, it appears that an off-site review process is more critical for blinded reviewers in comparison to an on-site interpretation in relation to the difficulty in reviewing an examination which was not performed personally and to the various image presentations from various machines or centres.

When examining individual lesions, it is possible to appreciate the role of CEUS in the diagnostic process. The high sensitivity implies that only a few diagnoses were not achieved using a contrast agent but the specificity was very high whatever the lesion type was. This indicates that, even in difficult patients, using CEUS, diagnosis is valid in more than 90% of cases with a very high specificity.

One important point is the reliability of the CEUS method compared to previously recommended methods such as contrast-enhanced CT or MRI. Ultrasound is a real-time method with strong advantages in terms of ease and cost, but it suffers from some limitations in terms of difficulty in reviewing a diagnosis on the basis of single frames with limited location landmarks and variability in machine settings. All these factors play a role in the limited use of conventional sonography for focal liver lesion diagnosis. The strong improvement in characterisation obtained by the use of contrast agents may emphasise the value of this method in place of the more expensive and less available imaging techniques as soon as the reliability of CEUS is validated.

The results demonstrate that concordance and kappa values between on-site and blinded off-site reviews are always

better with CEUS than with CT or MRI both in global population or by types of lesions. Until now, the performances of both examinations were only evaluated to underline the high accuracy of CEUS based on contrast-kinetic studies in arterial and late phase²⁰ or to show comparable performances of the two methods, but with higher specificity by CEUS.²⁴ However, Kim et al.⁶ have observed that inter-observer agreement was markedly improved by the use of contrast, kappa value being only 0.66 for conventional sonography but reached 0.92 for CEUS. In a multicentre study involving 127 patients Leen et al.¹⁷ reported a reduced inter-observer variability by using CEUS as assessed by a high kappa value of 0.66–0.77.

Some points need to be underlined to explain these results. The first concerns the diagnostic criteria used which were defined by the Rotterdam Consensus Conference.¹⁶ This implies that the same criteria were used by all investigators, thus reinforcing the diagnostic value of CEUS compared to conventional sonography in which diagnosis is more operator dependent. The second is that the variability between the machines used is lower when using contrast agents. Despite some differences in bubble detection sensitivity, the enhancement patterns are clearly seen leading to complete characterisation of a lesion. If these patterns are not observed, then no diagnosis is provided, but this is true for all the investigators. The third concerns the strict study protocol in which precise settings and recordings were initially defined for all methods. This is probably a key point in ultrasound examinations which are frequently too dependent on the physicians expertise and the stored frames. Clip storage allows a true review of the lesion which helps in the assessment of enhancement patterns. Moreover, this storage allows an appreciation of the relationship between the lesion and its environment as well as differences in enhancement.

Despite the recommendations, it appears critical to review the images provided by CT or MRI due to differences in the machine settings, sequence and local practice. This could influence the variability observed between on-site and blinded reviewer. In some cases, on-site diagnosis from one modality could be influenced by the results obtained by the other modality.

To our knowledge, this is the first time that ultrasound has been shown to be more reliable than CT or MR techniques in the assessment of focal liver lesion. These results confirm that standardisation is essential to improve diagnostic quality and reproducibility. In the past, standardisation was less common with conventional sonography, but current appropriate storage capacity and precise diagnostic criteria have increased the diagnostic accuracy of ultrasound. For these reasons, it now seems appropriate to include ultrasound in the list of reference modalities for an accurate diagnostic algorithm of focal liver lesion characterisation. This will markedly modify our current strategy by promoting a single session diagnosis, i.e. conventional sonography and CEUS leading to cost savings and reduced delays in patient management.

The presence of cirrhosis results in a slight decrease in CEUS performance. In a group of 171 non-cirrhotic patients the contrast-late phase provided a high accuracy whereas in cirrhotic patients the arterial phase was related to the different types of lesions.⁴ However, CEUS identified a high

number of hepatocellular carcinomas with a high specificity.^{6,22,25} This suggests that CEUS can be used in all patients with cirrhosis as soon as a nodule is detected by conventional ultrasound (as also pointed out in the Barcelona recommendations).

10. Conclusion

This study clearly indicates that CEUS using SonoVue® and the most recent contrast-specific softwares is an effective diagnostic tool for focal liver lesion characterisation in the place of other modalities such as CT and MR imaging. The high reliability of this method related to high standardisation and well-defined criteria reinforces the place of ultrasound methods in the diagnostic algorithm. This study underlines the need for specific training and method standardisation to guarantee high quality examination.

Conflict of interest statement

This study was granted by French Health Ministry as 'Innovation Techniques' in 2004–2007.

Role of funding source

The preparation of this article was supported by Bracco Imaging Spa. The sponsor imposed no restrictions on the investigators in the writing of this manuscript. The corresponding author had the final responsibility to submit for publication.

REFERENCES

- Nisenbaum HL, Rowling SE. Ultrasound of focal hepatic lesions. *Semin Roentgenol* 1995;**30**:324–46.
- Reinhold C, Hammers L, Taylor CR, Quedens-Case CL, Holland KJ, Taylor KJ. Characterization of local hepatic lesions with duplex ultrasound: findings in 198 patients. *AJR Am J Roentgenol* 1995;**164**:1131–5.
- Wernecke K, Rummeny E, Bongartz G, et al. Detection of hepatic masses in patients with carcinoma: comparative sensitivities of sonography, CT and MR imaging. *AJR Am J Roentgenol* 1991;**157**:731–9.
- Celli N, Gaiani S, Piscaglia F, et al. Characterization of liver lesions by real-time contrast-enhanced ultrasonography. *Eur J Gastroenterol Hepatol* 2007;**19**:3–14.
- Correas JM, Bridal L, Lesavre A, et al. Ultrasound contrast agents: properties, principles of action, tolerance, and artifacts. *Eur Radiol* 2001;**11**:1316–28.
- Bruix J, Sherman M. Management of hepatocellular carcinoma. *Hepatology* 2005;**42**:1208–36.
- Bryant TH, Blomley MJ, Albrecht T, et al. Improved characterization of liver lesions with liver-phase uptake of liver-specific microbubbles: prospective multicenter study. *Radiology* 2004;**232**:799–809.
- Ding H, Wang WP, Huang BJ, et al. Imaging of focal liver lesions: low-mechanical-index real-time ultrasonography with SonoVue. *J Ultrasound Med* 2005;**24**:285–97.
- Kim SH, Lee JM, Lee JY, et al. Value of contrast-enhanced sonography for the characterization of focal hepatic lesions in patients with diffuse liver disease: receiver operating characteristic analysis. *AJR Am J Roentgenol* 2005;**184**:1077–84.
- Leen E, Ceccotti P, Kalogeropoulou C, et al. Prospective multicenter trial evaluating a novel method of characterizing focal liver lesions using contrast-enhanced sonography. *AJR Am J Roentgenol* 2006;**186**:1551–9.
- Ricci P, Laghi A, Cantisani V, et al. Contrast-enhanced sonography with SonoVue: enhancement patterns of benign focal liver lesions and correlation with dynamic gadobenate dimeglumine-enhanced MRI. *AJR Am J Roentgenol* 2005;**184**:821–7.
- Wilson SR, Burns PN. An algorithm for the diagnosis of focal liver masses using microbubble contrast-enhanced pulse-inversion sonography. *AJR Am J Roentgenol* 2006;**186**:1401–12.
- Xu HX, Liu GJ, Lu MD, et al. Characterization of small focal liver lesions using real-time contrast-enhanced sonography: diagnostic performance analysis in 200 patients. *J Ultrasound Med* 2006;**25**:349–61.
- Konopke R, Kersting S, Bergert H, et al. Contrast-enhanced ultrasonography to detect liver metastases: A prospective trial to compare transcutaneous unenhanced and contrast-enhanced ultrasonography in patients undergoing laparotomy. *Int J Colorectal Dis* 2007;**22**:201–7.
- Dietrich CF, Kratzer W, Strobe D, et al. Assessment of metastatic liver disease in patients with primary extrahepatic tumors by contrast-enhanced sonography versus CT and MRI. *World J Gastroenterol* 2006;**12**:1699–705.
- Claudon M, Cosgrove D, Albrecht T, et al. Guidelines and good clinical practice recommendations for contrast enhanced ultrasound (CEUS). Update 2008. *Ultraschall Med* 2008;**29**:28–44.
- Leen E, Ceccotti P, Kalogeropoulou C, Angerson WJ, Moug SJ, Horgan PG. Prospective multicenter trial evaluating a novel method of characterizing focal liver lesions using contrast-enhanced sonography. *AJR Am J Roentgenol* 2006;**186**:1551–9.
- Quaia E, Calliada F, Bertolotto M, et al. Characterization of focal liver lesions with contrast-specific US modes and a sulfur hexafluoride-filled microbubble contrast agent: diagnostic performance and confidence. *Radiology* 2004;**232**:420–30.
- von Herbay A, Vogt C, Willers R, Häussinger D. Real-time imaging with the sonographic contrast agent SonoVue: differentiation between benign and malignant hepatic lesions. *J Ultrasound Med* 2004;**23**:1557–68.
- Burns P, Wilson S. Focal liver masses: Enhancement patterns on contrast-enhanced images – concordance of US scans with CT scans and MR images. *Radiology* 2007;**242**:162–74.
- Bleuzen A, Tranquart F. Incidental liver lesions: diagnostic value of cadence contrast pulse sequencing (CPS) and SonoVue. *Eur Radiol* 2004;**14**(Suppl. 8):53–62.
- Nicolau C, Vilana R, Catala V, et al. Importance of evaluating all vascular phases on contrast-enhanced sonography in the differentiation of benign from malignant focal liver lesions. *AJR Am J Roentgenol* 2006;**186**:158–67.
- Dietrich CF, Mertens JC, Braden B, et al. Contrast-enhanced ultrasound of histologically proven liver hemangiomas. *Hepatology* 2007;**45**:1139–45.
- Catala V, Nicolau C, Vilana R, et al. Characterization of focal liver lesions: comparative study of contrast-enhanced ultrasound versus spiral computed tomography. *Eur Radiol* 2007;**17**:1066–73.
- Liu GJ, Xu HX, Lu MD, et al. Enhancement pattern of hepatocellular carcinoma: comparison of real-time contrast-enhanced ultrasound and contrast-enhanced computed tomography. *Clin Imag* 2006;**30**:315–21.